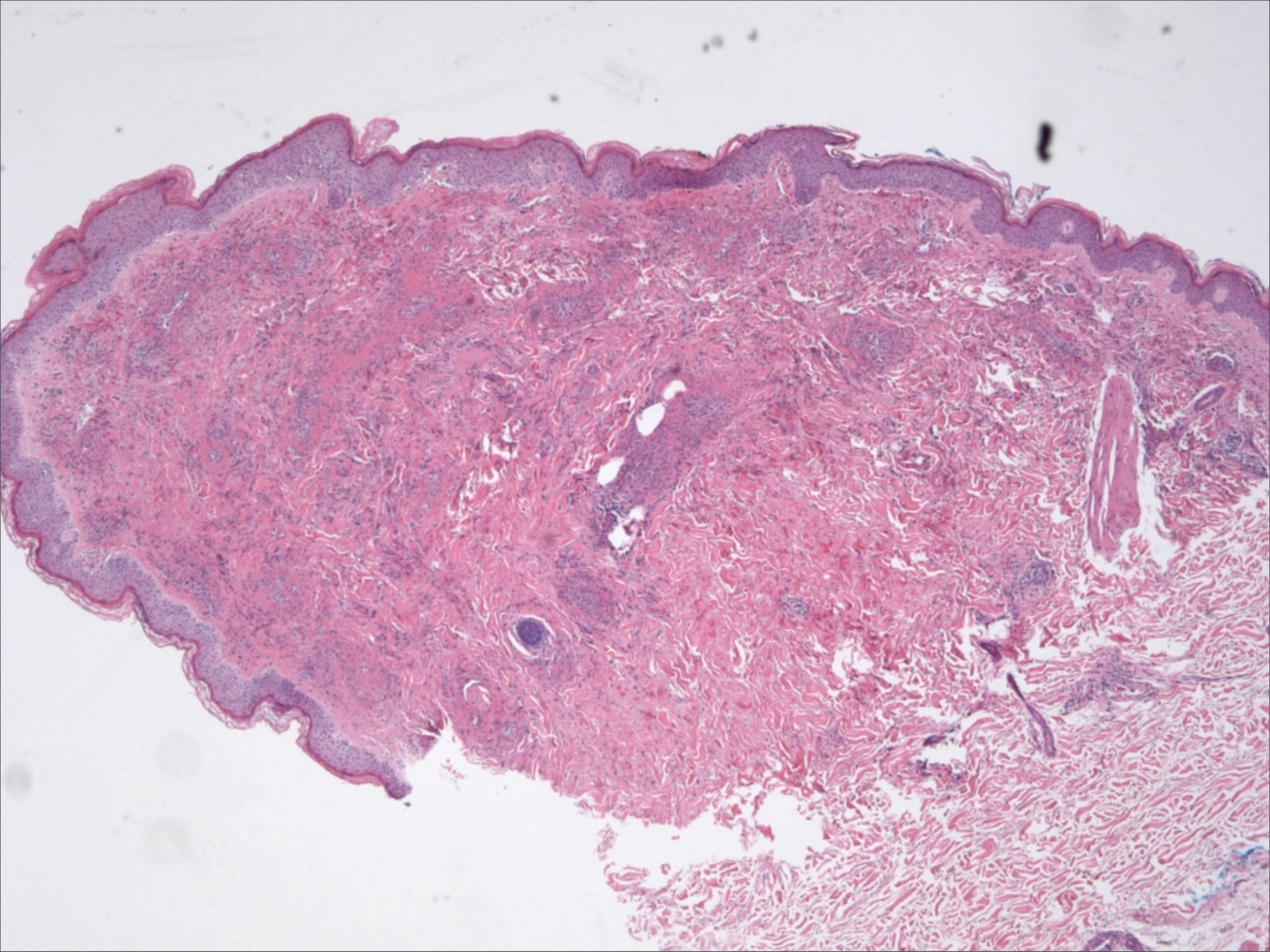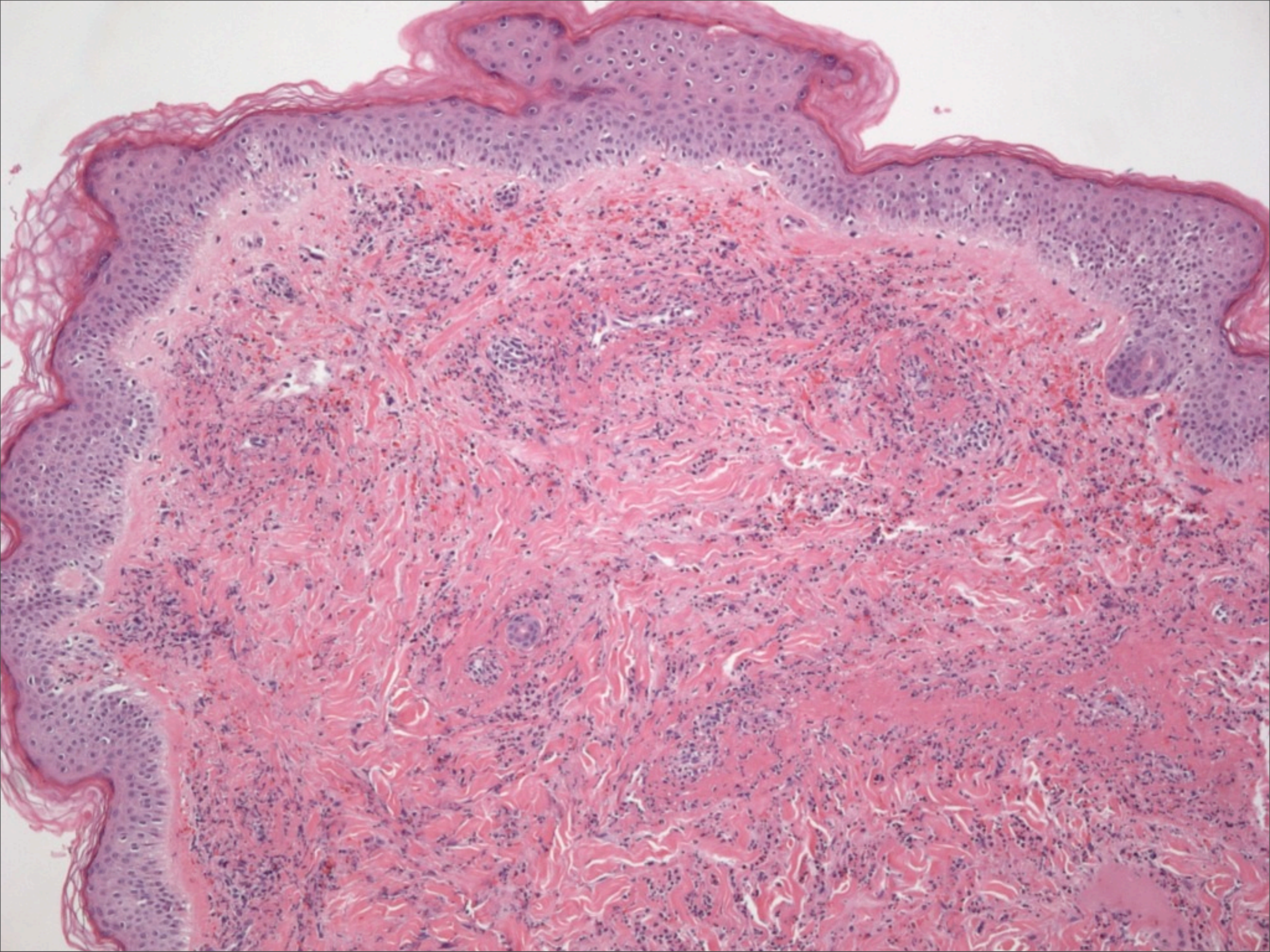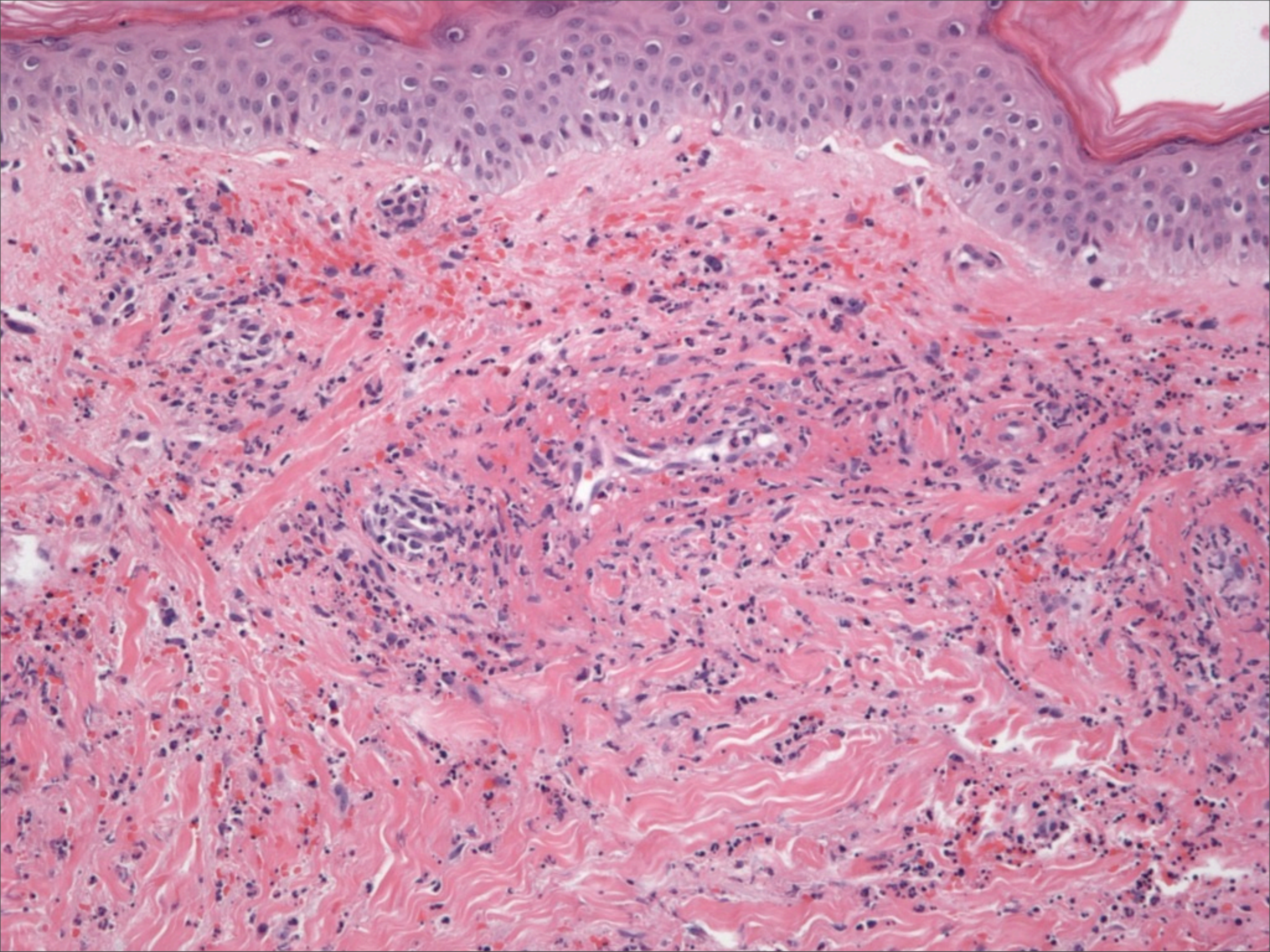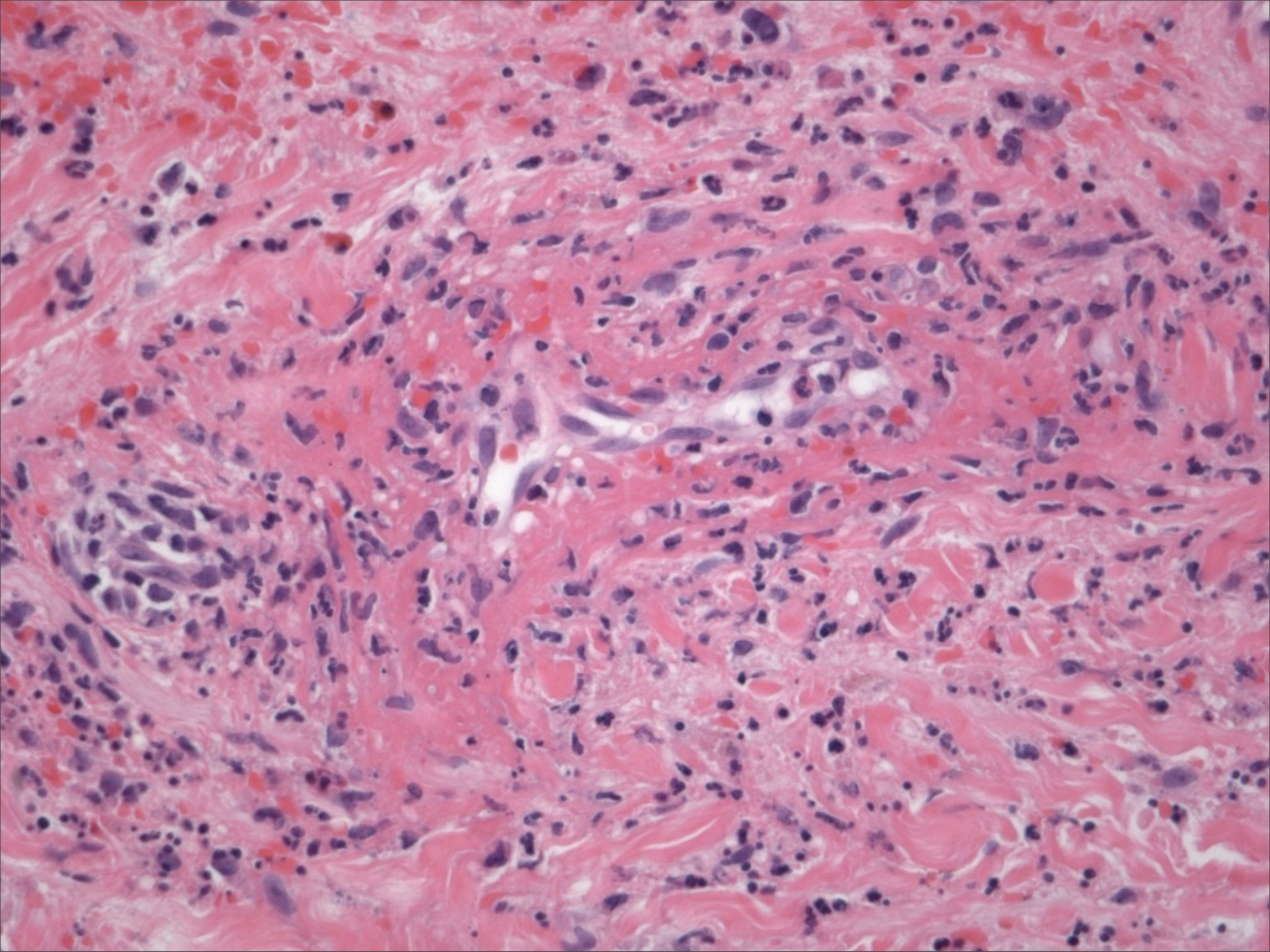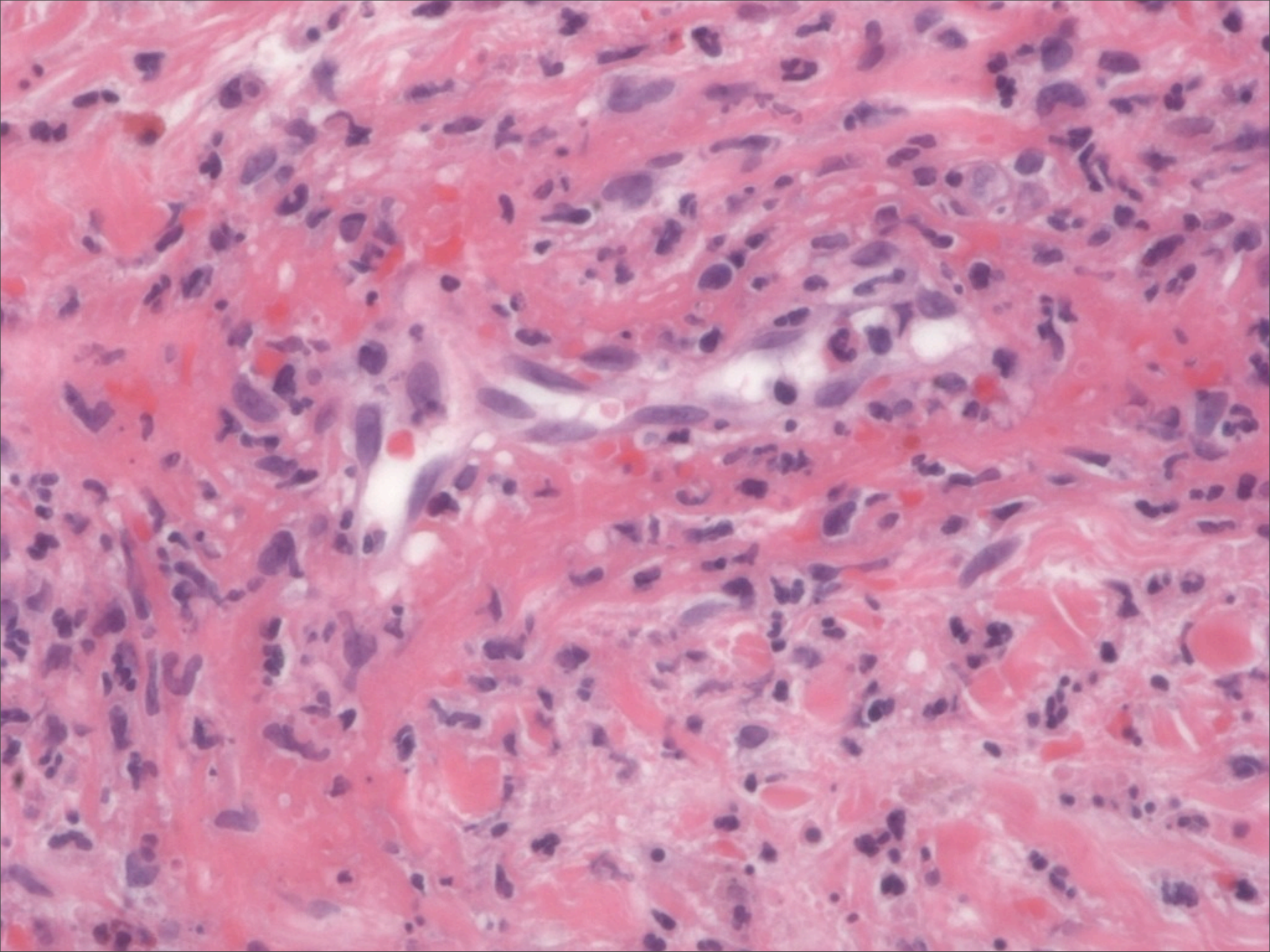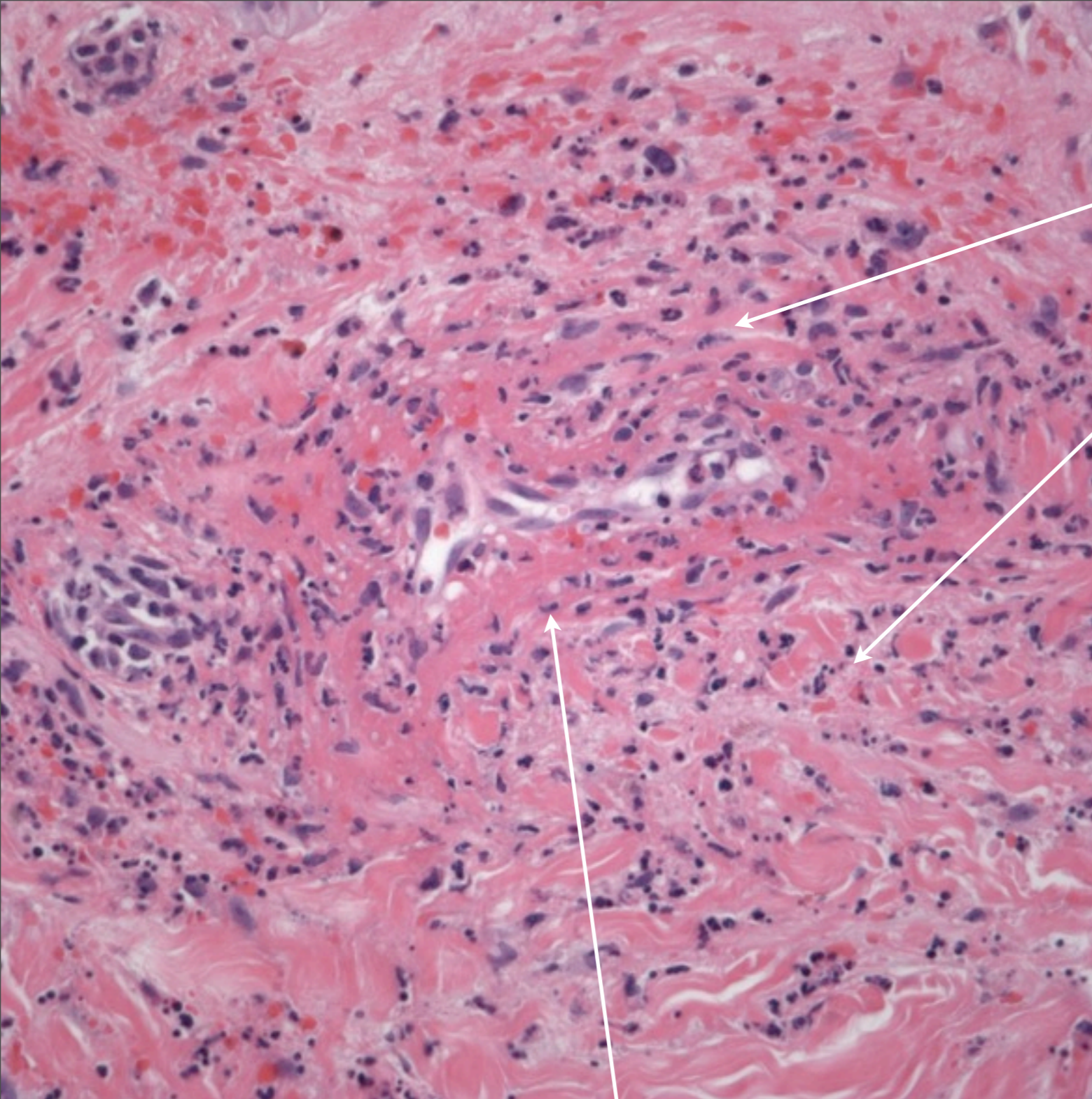


# Leukocytoclastic Vasculitis



Nuclear dust

Dermal hemorrhage

Fibrinoid necrosis-MUST SHOW THIS